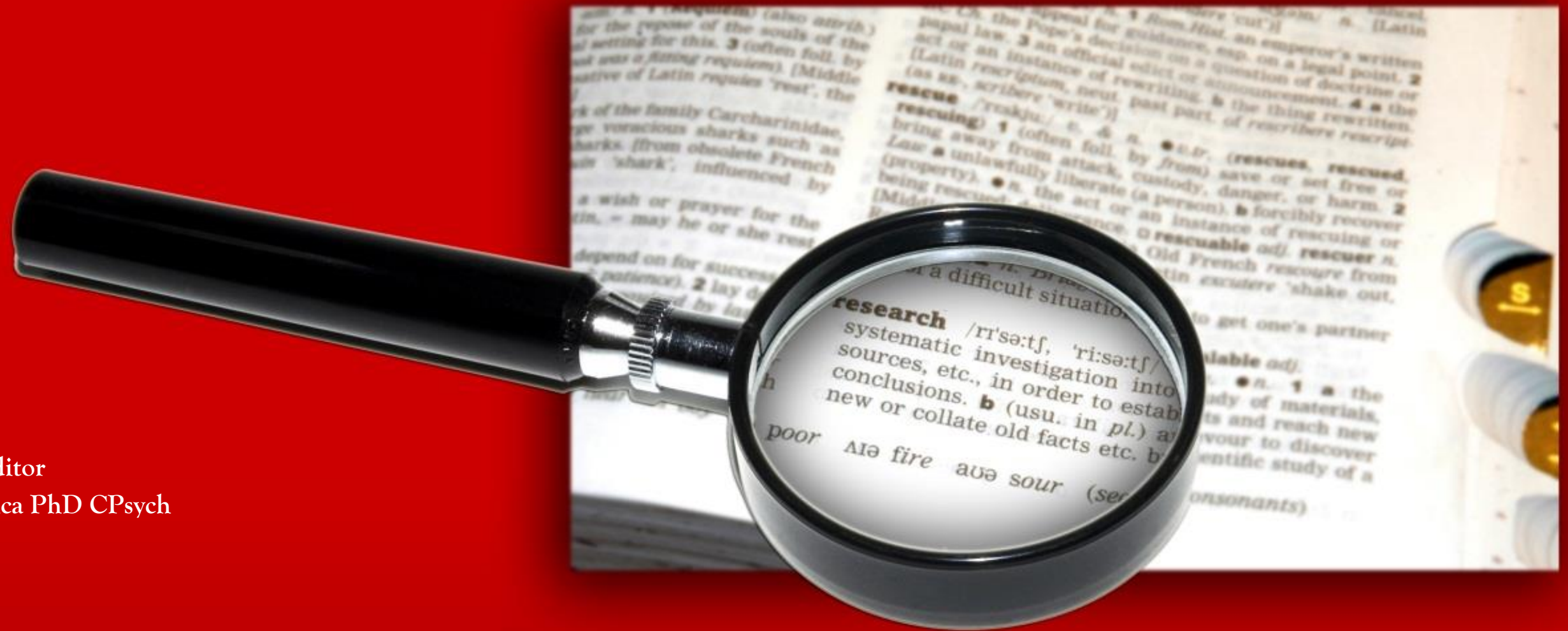

# Research INSIGHTS



Editor  
J. D. Mendonca PhD CPsych

JANUARY 2017 | VOL 14 No. 1

REVIEW AND A PROOF-OF-CONCEPT PROPOSAL

Inflammation-Associated Depression

*Research Insights* is a peer-reviewed journal designed to publish reviews, case studies and research articles authored by the mental health professionals of Parkwood Institute and Southwest Centre for Forensic Mental Health Care of St. Joseph's Health Care London (which is affiliated with Lawson Health Research Institute).

*Research Insights* may also provide a forum for preliminary results of ongoing research.

### **Editor**

J.D. Mendonca PhD, CPsych

### **Instructions for Authors**

Manuscripts submitted for publication must follow the rules of APA Style<sup>®</sup>, detailed in the *Publication Manual of the American Psychological Association*. The manuscript should include the following main sections:

(1) Title Page; (2) Abstract (maximum of 250 words) , and up to five key words or brief phrases; (3) Introduction; (4) Method; (5) Results; (6) Discussion; (7) References; (8) Appendices. We ask that papers not exceed 4000 words. For more details, please visit the APA website at <http://www.apa.org/pubs/authors/instructions.aspx> and a helpful tutorial can be found at: <http://www.apastyle.org/learn/tutorials/basics-tutorial.aspx>

Brief Report manuscripts may be submitted for publication and should not exceed 1500 words. The *Brief Report* manuscript should include the following:

(1) Title Page; (2) Succinct Abstract; (3) Introduction (include background highlights with a clear 'purpose' statement; (4) Method; (5) Results (using a maximum of 1 table or figure if necessary); (6) Discussion (a concise outline of clinical implications and/or expected outcomes); (7) References; (8) Appendix.

The Editor may be approached for any unique manuscript stylistic variations required by the subject matter.

Parkwood Institute  
Mental Health Care Building  
Research and Education Unit  
550 Wellington Road  
London, ON N6C 0A7  
Telephone: 519-455-5110 ext. 47240  
Facsimile: 519-455-5090

**ISSN 2368-6294 (Print)**  
**ISSN 2368-6308 (Online)**

---

# *Review and a Proof-of-Concept Proposal*

## **Inflammation-Associated Depression**

### **Contents**

#### **Vol. 14, No. 1 January 2017**

#### **Inflammation and Depression: What Can We Learn from Emerging Molecular Neuroimaging Modalities? Page 2**

*Nicole M. Marlatt, Amer M. Burhan, Lena Palaniyappan*

#### **Corresponding author:**

Nicole Marlatt (nicole.marlatt@sjhc.london.on.ca)

#### **Hybrid Imaging: A Proof-of-Concept Attempt at Understanding Neuroinflammation in Depression Page 15**

*Nicole M. Marlatt, Amer M. Burhan, Lena Palaniyappan*

#### **Corresponding author:**

Lena Palaniyappan (lena.palaniyappan@lhsc.on.ca)

Parkwood Institute Mental Health Care  
550 Wellington Road  
London, ON N6C 0A7  
Phone: 519-646-6100 ext. 47240  
Fax: 519-455-5090

---

## *Inflammation and Depression: What can we learn from Emerging Molecular Neuroimaging Modalities?*

---



**Nicole M. Marlatt, PhD.**

*Project Manager of Mental Health Research, St. Joseph's Health Care London, London, Ontario*



**Amer M. Burhan, MBChB, MSc., FRCPC.**

*Geriatric Neuropsychiatrist and Neurostimulation Clinic Lead, St. Joseph's Health Care London, London, Ontario*



**Lena Palaniyappan, MBBS, PhD**

*Psychiatrist and Director of the Prevention and Early Intervention Program in Psychosis (PEPP), London Health Sciences Centre, Victoria Hospital, London, Ontario*

**Key words:** Depressive Disorders, Inflammation-Associated Depression, Molecular Neuroimaging, Treatment-Resistant Depression, Positron-Emission Tomography, Hybrid Imaging, Neuroinflammation

### **ABSTRACT**

*Depressive symptoms are common in patients with inflammatory illnesses. However, the mechanism of the association between the immune response and depression as a disorder is still widely unknown and is a current focus of many research studies. Inflammation could be either causative or merely an adaptive response in depression. Regardless, it is currently well documented that depression is associated with both chronic inflammation and cell-mediated inflammatory responses. In this review we highlight how emerging molecular imaging technologies can provide valuable insight into the role inflammation plays in depressive disorders. The review focuses mainly on positron-emission tomography (PET) and the emerging radioligands that have been developed specifically to understand inflammation of the brain. Studies designed to investigate specific sub-categories of individuals' inflammatory response to depression will be the most informative in understanding the etiology and pathogenesis of depressive disorders. This may be achieved by imaging monoaminergic and non-monoaminergic mechanisms with inflammation targets in the same subject. Strategically planning experiments and combining information from more than one PET radioligand and by using hybrid-imaging techniques such as PET/Magnetic Resonance Imaging (MRI) can further provide valuable insight into the molecular basis of inflammation-associated depression.*

## Background Highlights

Depression is a common mental disorder that has been recognized as the leading cause of disability worldwide by the World Health Organization ([www.who.int/mediacentre/factsheets/fs369/en/](http://www.who.int/mediacentre/factsheets/fs369/en/)).

With almost sixty years of neurobiological research, the current understanding of depression is that it is multifactorial and heterogeneous, with many genetic and environment factors contributing to the onset of the disorder. Depression is therefore not a disease in a narrow sense, as its etiology and mechanistic properties of pathogenesis are largely unclear. It is more accurately classified as a syndrome; defined by a set of symptoms that can manifest as excessive or insufficient in nature compared to normative function (e.g. sleep or appetite). Clinicians rely on the symptom-based diagnostic approach described within the Diagnostic and Statistical Manual of Mental Disorders (DSM-V) (American Psychiatric Association, 2013), but depression can encompass a number of disorders, with the severe form known as major depressive disorder (MDD), sometimes being resistant to treatment (Fava, 2003). When using DSM-V guidelines to diagnose MDD, there are 256 different ways of being depressed (i.e. various combinations of 5 or more of the 9 symptoms set-out by the diagnostic guidelines). Therefore, it is not very difficult to diagnose depression, the difficulty lies in identifying and targeting the variance found in depressive disorders with the proper therapeutic intervention.

The persistent nature of depression as a global public health problem is partly caused by the limited efficacy of current therapies. It is estimated that approximately two-thirds of all patients diagnosed with MDD either do not achieve remission or continue to relapse after adequate treatment has been provided (Rush et al., 2006). By using neuroscience research, inter-individual differences in treatment efficacy can be uncovered to reverse the subject-specific pathophysiology of depression (O'Leary, Dinan, & Cryan, 2015). Such an approach can clarify the subtypes of this heterogeneous illness, and help match treatments to neurobiological mechanisms.

While the symptoms and epidemiology of depression are well documented, the pathophysiology and etiology are largely unknown. Significant evidence suggests that brain monoaminergic systems play a key role in the pathogenesis of depression. However, the lack of response to treatment with monoaminergic modulators (i.e. selective serotonin reuptake inhibitors (SSRI's), serotonin norepinephrine reuptake inhibitors (SNRI)), and the fact that not all symptoms of depression can be related to dysfunctions in monoaminergic systems suggests that other factors contribute to the expression, maintenance and variance seen in depressive disorders. In the last two decades the role of the immune system in the pathogenesis of depressive disorders has been widely studied (Bhattacharya, Derecki, Lovenberg, & Drevets, 2016; Haapakoski, Ebmeier, Alenius, & Kivimaki, 2016; Wager-Smith & Markou, 2011). The strong association between the inflammatory response and depression (Maes et al., 2012) indicates a subclass of depression that can be referred to as being inflammation-associated. A better understanding of this variant form of depression is needed and can potentially reveal new therapeutic targets for this disorder. We provide a brief overview of the current understanding of inflammation-associated depression and provide future molecular imaging study designs that could shed light on the pathophysiology of inflammation and reveal the association with depression.

## Overview of Inflammation

Inflammation is a complex multicellular process and an evolutionary mechanism by which the immune system maintains homeostasis. It is a necessary response to infection and cell damage, but can also be destructive when stimulated inappropriately or out of proportion to a given stimuli.

The immune system can be divided into the innate and adaptive systems. The innate system defends from infection and other organisms. The cells of the innate system recognize pathogen-associated molecular patterns, undergo activation and release inflammatory mediators (e.g. histamine, bradykinin,

and prostoglandins). The inflammatory response causes vasodilation of the blood vessels and attracts immune cells like neutrophils and macrophage. The macrophage cells release cytokines (interleukin (IL)-1, IL-6, and tumour necrosis factor (TNF)- $\alpha$ ) that prolong the inflammatory response and attract leukocytes and lymphocytes to initiate the adaptive immune system to provide immunological memory and long-lasting protection.

Microglia are the brain's immune cells, with a macrophage-lineage derived from hematopoietic progenitors. Microglia can detect and react to alterations in brain homeostasis, such as infection, trauma and degeneration. These cells were historically thought to be activated only upon neuronal damage or in the case of neurodegeneration to act as the brain's own macrophage by cleaning up cellular debris. It is now understood that microglia have multiple functions and are not dormant even when inactive. They participate in neurogenesis (Sierra et al., 2010), regulate functional synapse (Schafer et al., 2012), and upon activation release proinflammatory cytokines (IL-1, IL-6, and TNF- $\alpha$ ) in response to different pathological states within the CNS (Smith, Das, Ray, & Banik, 2012). The brain was once considered an immune-privileged organ, but recent research suggests that the CNS and peripheral immune system have a bidirectional relationship where the CNS and the immune system can influence one another (Jacobs, Tavitian, & INMiND Consortium, 2012).

### **History and Evidence of Inflammation-Associated Depression**

The relationship between mental disorders and inflammation was first postulated as early as 1887 by psychiatrist Julius Wagner-Jauregg (Nobel Prize Laureate 1927) (Raju, 1998). However, for many years after, inflammation and its association with mood disorders were neglected because of the development of relatively effective antidepressant medications such as SSRI's and others. It is now becoming clear though that the efficacy and efficiency of these medications is limited, as many

patients with MDD, for example, remain treatment-resistant despite adequate dosing and duration with these existing pharmacotherapies. It was not until the early 1990's that the *Macrophage Theory of Depression* was postulated by Roger Smith (Smith, 1991) describing evidence that depression was an inflammatory condition. The theory was based on clinical studies with non-depressed cancer patients being treated with proinflammatory cytokines. The patients developed symptoms that satisfied the diagnostic criteria for clinical depression and the symptoms dissipated when the treatment was stopped. This suggested that inflammatory mediators in excess (cytokines) play a role in causing depressive disorders. Excessive secretion of macrophage cytokines such as IL-1, TNF- $\alpha$ , and interferon (IFN)- $\alpha$  are hypothesized to have a causal role in some patients with major depression. Experiments conducted later by Maes and colleagues, showed that patients with depression exhibit higher plasma concentrations of proinflammatory IL-6, IL-2 and TNF $\alpha$  than those not suffering from a mental disorder (Maes et al., 1995).

Several additional studies have come to light in the last few decades to support an immunological etiology of MDD (Dahl et al., 2014; Eyre & Baune, 2012; Money et al., 2016). Indeed, several studies have shown a significant increase in the production of proinflammatory cytokines among depressed patients (Rosenblat, Cha, Mansur, & McIntyre, 2014). In 2009, a meta-analysis reinforced the previous research by reporting that there was a positive correlation between depression and inflammation for certain markers of inflammation (IL-6, IL-1, etc.), with a reliable dose-dependency where concentrations of cytokines in plasma and the cerebrospinal fluid (CSF) peak during mood episodes and drop during euthymic periods (Howren, Lamkin, & Suls, 2009).

A growing amount of evidence is now suggesting that proinflammatory cytokines induce depressive-like behaviors. Reichenberg et al. (2001) gave healthy participants endotoxin injections to trigger an

inflammatory response (Reichenberg et al., 2001). The findings showed elevated cytokine release, and a depressed mood. Wright et al. (2005) had similar findings when vaccinating healthy volunteers against typhoid. The *Salmonella typhi* vaccine increased cytokine levels (IL-6, TNF $\alpha$  and others) through an acute inflammatory response and resulted in a negative mood with symptoms consistent with depression (Wright, Strike, Brydon, & Steptoe, 2005).

With a tremendous amount of research to support the role of inflammation in depression (Krishnadas & Cavanagh, 2012), the next logically step for researchers was to test whether inhibiting inflammation reduces depressive symptoms. Many clinical trials are underway involving anti-inflammatory medications in reducing depressive symptoms. Some notable studies such as that using TNF- $\alpha$  antagonists (prescribed to reduce systemic inflammation in psoriasis) decrease depressive symptoms (Krishnan et al., 2007). A meta-analysis of ten placebo-controlled, double-blind clinical trials in which patients with depression were treated with omega-3 polyunsaturated fatty acids produced a decreased inflammatory response and a modest antidepressant effect (Song & Zhao, 2007).

### ***Neuroinflammation is Associated with Treatment-Resistant Depression***

Currently most marketed antidepressant drugs have been developed on the basis of treating monoamine neurotransmitter imbalances in depression. Despite advances with these classes of medication, one-third of patients suffering from MDD fail to respond to conventional antidepressant medication (Rush et al., 2006). One pathophysiologic mechanism hypothesized to contribute to treatment resistance in depression is central nervous system (CNS) inflammation (aka neuroinflammation).

To date, inflammation has been confirmed in various clinical populations, but accounts for only a small population variance. A number of inflammatory biomarkers (including inflammatory cytokines,

chemokines, and adhesion molecules) outside of the CNS have been found to be reliably elevated in one-third of all depressed patients and inadvertently have a decreased likelihood of response to conventional antidepressants (Lanquillon, Krieg, Bening-Abu-Shach, & Vedder, 2000; Miller, Maletic, & Raison, 2009). Therefore, an association between depression and inflammation is promising with regard to finding additional therapeutic targets for treating MDD, especially for those who fail to respond to conventional treatments. A thorough understanding of the non-monoamine mechanisms and molecular pathways associated with neuroinflammation will enable the discovery and implementation of new diagnostic and therapeutic strategies for a wide-range of neuroimmunological conditions including depression. Recent advancements in neuroimaging may pave the way to understanding the molecular basis of inflammation and its connection to depression.

### ***Imaging Brain Inflammation at the Molecular Level***

Molecular imaging can measure, visualize and characterize the molecular and cellular biological processes in humans (Mankoff, 2007). There are many imaging modalities that are capable of molecular imaging including magnetic resonance imaging (MRI), positron-emission tomography (PET), single-photon emission computed tomography (SPECT), though the high sensitivity and specificity of PET makes it one of the most popular molecular techniques for clinical utility. PET uses molecules that are radio-labelled with a positron-emitting nuclide, which is injected into the patients bloodstream, enters the brain and, binds to target molecules. Generally speaking, these imaging agents can be divided into two key types, one molecule type has a high affinity for ion channels, transporters or specific receptors such as translocator protein (TSPO) (aka peripheral benzodiazepine receptor (PBR)), another uses a molecular technique that can be used to target metabolism or enzymatic activity. Several neuroinflammation-related targets including TSPO, cannabinoid receptor-2 (CB<sub>2</sub>R), and

cyclooxygenase-2 (COX-2) have been identified (Ory, Celen, Verbruggen, & Bormans, 2014; Pulli & Chen, 2014). Among them, TSPO is the most popular target for PET imaging that is already being used for clinical applications in humans, while CB<sub>2</sub>R and COX-2 radioligands are still being tested in animals.

### **Targeting Translocator Protein (TSPO)**

Research has shown that chronic neuroinflammatory diseases are caused by activated microglia in the CNS (Jacobs et al., 2012; Streit, Mrazek, & Griffin, 2004). These CNS resident immune cells are also activated in the acute neuroinflammation phase and protect brain tissue from further injury. PET tracers are constantly being developed to investigate neuroinflammation through the molecular constituents that play a role in the cascade of events (Pulli & Chen, 2014). Currently, PET is the most widely used imaging modality for *in vivo* methods of detecting microglial activation. *In vivo* imaging probes have been developed to specifically detect the expression of TSPO. This protein is ubiquitously expressed in peripheral tissues, but is only minimally expressed in the healthy human brain. Previous studies found high TSPO expression in macrophages, neutrophils, lymphocytes (Bird et al., 2010; Gaemperli et al., 2012), activated microglia, and astrocytes (Lavisse et al., 2012). The exact function of TSPO in the CNS is not yet known, but it is thought to have a role in transporting cholesterol and amino acids and in steroid production (Banati, 2002). TSPO is now considered a hallmark of neuroinflammation through its connection with microglial activation (Chauveau, Boutin, Van Camp, Dolle, & Tavitian, 2008).

Using PET imaging, Setiawan et al. (2015) showed that clinically depressed patients (having a major depressive episode) had significantly higher levels of brain inflammation in comparison with healthy participants and the highest levels of inflammation was associated with the most severe depression (Setiawan et al., 2015). The study used radioligand [<sup>18</sup>F]-FEPPA (Wilson et al., 2008) that binds to TSPO found on the outer mitochondrial membrane in

microglia and increased expression is associated with microglia activation that occurs during neuroinflammation (Rupprecht et al., 2010). However, TSPO levels measured with radioligand [<sup>13</sup>C]-PBR28 were not found to be elevated in mild-to-moderately depressed subjects (Hannestad et al., 2013). Since [<sup>18</sup>F]-FEPPA and [<sup>13</sup>C]-PBR28 are both suitable TSPO binding radioligands for detecting microglia activation, the reason for opposite conclusions from these two studies is not obvious. It may be related to the different level of depression being studied or the heterogeneity of the participant pool. More clearly, when translocator protein levels were measured with [<sup>13</sup>C]-PBR28, the participants in the study pool differed from mild to moderately depressed, treated, symptomatic, untreated, or partially symptomatic (Hannestad et al., 2013). In contrast, Setiawan et al. (2015) was looking at participants with similar depression severity who were medication free for at least 6 weeks prior to the brain imaging scans. Other factors such as the region of the brain being scanned and study exclusion criteria (i.e. concurrent active Axis I disorders, including current alcohol or substance dependence, major depressive episodes with psychotic symptoms, bipolar I or II disorder, and borderline or antisocial personality disorder) were also not consistent between the two studies and could also account for the conclusions drawn from each of them.

### **Imaging Cyclooxygenase (COX)**

Cyclooxygenase (COX), also known as prostaglandin H, is an enzyme responsible for the conversion of arachidonic acid into prostaglandins, which has been shown to contribute to neuroinflammation (Farooqui, Horrocks, & Farooqui, 2007). COX is also the target of non-steroidal anti-inflammatory drugs (NSAIDs) (Hawkey & Yeomans, 1999). In addition, COX is an integral membrane glycoprotein, which can be induced by acute and chronic inflammatory stimulations. Three COX isoforms have been uncovered with the inducible isoform COX-2 displaying a role in cancer, Alzheimer's/Parkinson's disease, and response to inflammatory stimuli, especially neuroinflammation (Katori & Majima,



2000; Minghetti, 2004). Celecoxib™, is a common COX-2 inhibitor drug and when used with antidepressant Reboxetine™ improves symptoms more effectively than when the antidepressant is combined with a placebo (Muller et al., 2006). Imaging of COX-2 has been an ongoing challenge due to specificity and hydrolysis of the radioligand (Ory et al., 2014), and as such is still in the pre-clinical stages.

### ***Other Targets of the Neuroinflammation Process***

Challenges with the blood-brain barrier (BBB) and the research community's limited understanding of neuroinflammation molecular target function has required an extensive amount of effort in developing neuroinflammation radioligands. Recent advancements into this field have been reviewed elsewhere (Ory et al., 2014; Wu, Li, Niu, & Chen, 2013). Many groups are targeting developments to the endocannabinoid system, such as the cannabinoid receptors (CBRs) due to their association with immune-mediated pathologies. CB<sub>2</sub>R, for example, is found on activated microglia, the resident immune cells in the CNS (Cabral, Raborn, Griffin, Dennis, & Marciano-Cabral, 2008). PET radiotracer [<sup>11</sup>C]-NE40 has been recently used in humans and is showing promise for brain imaging of CB<sub>2</sub>R (Ahmad et al., 2013). Other targets of neuroinflammation that are currently being investigated include receptors: histamine-4-receptor (H4R), P<sub>2</sub>X<sub>7</sub> receptor, and enzymes monoamine oxidase-B and matrix metalloproteinase. However, these radiotracers are in preliminary stages of development and only time will inform the future of PET neuroinflammation imaging.

### ***Molecular Imaging in Understanding the Pathological Aspects of Inflammation in Depression***

Depression appears to be a multifactorial syndrome that is influenced by many molecular modulators and mechanisms. Neuroinflammation cascades, for example, appear to have a significant influence on

depression variance. Indeed, multiple trials involving combinatorial therapies between anti-inflammatory type medications and conventional antidepressants targeting monoaminergic systems are underway (Kohler, Krogh, Mors, & Benros, 2015). However, the efficacy of these complex pharmacotherapy attempts will likely hit the same plateau that conventional antidepressants have faced unless a better understanding of the molecular basis of depression and subgrouping of patients is done to provide proof-of-concept evidence (Gelenberg et al., 2008). These drug trials seem to be premature in the absence of sufficient knowledge on the pathophysiological mechanisms linking inflammation to depression.

PET imaging with multiple imaging probes may provide the necessary evidence to create a coherent and comprehensive clinical model of inflammation-associated depression. Co-investigating molecular aspects of inflammation and monoamine systems known to be affected by depression could provide a point of leverage beyond the present dilemma; improving the information known regarding antidepressant drugs and CNS effects.

Unlike neuroinflammation, multiple PET radioligands have been developed and approved for use in humans that are capable of imaging monoamine systems (e.g. serotonin and dopamine) and non-monoaminergic mechanisms ( $\gamma$ -aminobutyric acid (GABA)) involved in depressive disorders (Lee, Quek, & Krishnan, 2014). Few studies have tried to connect inflammation with direct neurotransmission in the brain to date. It has been noted though that systemic proinflammatory cytokines can access the CNS and interfere with serotonin metabolism, reduce both synaptic plasticity and hippocampal neurogenesis (Caraci, Copani, Nicoletti, & Drago, 2010; Maes, 2011), which is associated with behavioral consequences including depression (Capuron & Miller, 2011). Therefore, simultaneous combinatorial imaging studies incorporating multiple imaging probes that target metabolic function, inflammation, as well as

monoaminergic and non-monoaminergic mechanisms may provide insight into the direct relationship between depressive symptoms and neuroinflammation.

One of the most needed imaging studies is one that is designed to show a direct relationship between inflammation and depression. One possibility for this type of study would be one that simultaneously images microglia activation (TSPO) and the cellular destruction that is consistent with depression. This would either support or dismiss inflammation as a causative agent in depression. Based on our current understanding of neuroinflammation, imaging TSPO, glutamate and grey matter volume in the brain may address this type of question. This is because activated microglia are known to release the excitotoxic glutamate upon activation, which if persistent/repetitive can cause grey matter lesions, similar to the ones reported in depression (Goodkind et al., 2015). This type of study would involve simultaneous PET imaging (TSPO) and MRI (grey matter and glutamate measurement). Emerging hybrid PET/MRI allows simultaneous observations of the relevant molecular targets and could provide proof-of-concept support for inflammation-associated depression (Burhan, Marlatt, Palaniyappan, Anazodo, & Prato, 2015).

### ***Strategically Selecting Participants***

Since depression can be extremely multifactorial, the most informative studies will be those that ensure the correct subclass of patients is being investigated in the same study. Heterogeneous participate pools (i.e. those treated, untreated, symptomatic etc.) can lead to confusion when comparing imaging data within a study and between studies. In previous TSPO binding studies, for example, Setiawan et al. (2015) concluded that TSPO is elevated in depression, whereas Hannestad et al. (2013) found no significant elevation. Further studies are now warranted to clarify this discrepancy, preferably to rule out the possibility that TSPO activation may be stage-specific, severity specific, treatment-exposure specific and also subtype-specific in depression.

Appropriately selecting and matching patients based on this criterion will give more validity to the conclusions that can be drawn from future studies.

Another cautionary note should be added regarding imaging subjects taking antidepressant medications. These drugs have immunoregulatory activities especially on cytokine production (Szuster-Ciesielska, Tustanowska-Stachura, Slotwinska, Marmurowska-Michalowska, & Kandefer-Szerszen, 2003). Specifically, SSRI's, tricyclic antidepressants and heterocyclic antidepressants inhibit the production of proinflammatory cytokines (TNF $\alpha$ , IL-1, IFN- $\gamma$ ) and increase production of anti-inflammatory cytokine IL-10 (Maes, Song, Lin, Bonaccorso, et al., 1999; Xia, DePierre, & Nassberger, 1996). Lithium also shows a significant immunoregulatory effect by increasing IFN $\gamma$ , TNF $\alpha$  and IL-8 and negative immunoregulatory cytokines or proteins (IL-10 and the IL-1 receptor agonist), possibly restoring any disequilibrium in the secretion of proinflammatory versus anti-inflammatory mediators (Maes, Song, Lin, Pioli, et al., 1999). These medications may influence whether inflammation biomarkers are detected, and could fail to reveal an underlying association with depression.

### **Conclusion**

Current data indicates that inflammation is strongly *associated* with the pathophysiology of a subset of depression cases. To discover whether inflammation is causative or an adaptive aspect of depression will require a better overall understanding of the mechanisms at the molecular and cellular level. Emerging molecular neuroimaging modalities will assist in this learning. By using strategies involving hybrid imaging and/or by combining multiple PET radioligands in the studies, we can learn how microglial activation brings about the region-specific changes of depression; how monoamine systems and non-monoaminergic mechanisms are affected by inflammation; and whether treatment-resistance is a particular feature of the inflammation-based subtype. With molecular imaging techniques and proper selection of study subjects, a better understanding of

the molecular pathophysiology of depression will be achieved.

## References

- Ahmad, R., Koole, M., Evens, N., Serdons, K., Verbruggen, A., Bormans, G., & Van Laere, K. (2013). Whole-body biodistribution and radiation dosimetry of the cannabinoid type 2 receptor ligand [11C]-NE40 in healthy subjects. *Molecular Imaging and Biology*, *15*(4), 384-390. doi: 10.1007/s11307-013-0626-y
- American Psychiatric Association (2013). Diagnostic and Statistical manual of mental disorders In t. edition (Ed.), (5th edition ed.). Arlington, VA.
- Banati, R. B. (2002). Visualising microglial activation in vivo. *Glia*, *40*(2), 206-217. doi: 10.1002/glia.10144
- Bhattacharya, A., Derecki, N. C., Lovenberg, T. W., & Drevets, W. C. (2016). Role of neuro-immunological factors in the pathophysiology of mood disorders. *Psychopharmacology (Berl)*. doi: 10.1007/s00213-016-4214-0
- Bird, J. L., Izquierdo-Garcia, D., Davies, J. R., Rudd, J. H., Probst, K. C., Figg, N., . . . Warburton, E. A. (2010). Evaluation of translocator protein quantification as a tool for characterising macrophage burden in human carotid atherosclerosis. *Atherosclerosis*, *210*(2), 388-391. doi: 10.1016/j.atherosclerosis.2009.11.047
- Burhan, A. M., Marlatt, N. M., Palaniyappan, L., Anazodo, U. C., & Prato, F. S. (2015). Role of Hybrid Brain Imaging in Neuropsychiatric Disorders. *Diagnostics (Basel)*, *5*(4), 577-614. doi: 10.3390/diagnostics5040577
- Cabral, G. A., Raborn, E. S., Griffin, L., Dennis, J., & Marciano-Cabral, F. (2008). CB2 receptors in the brain: role in central immune function. *British Journal of Pharmacology*, *153*(2), 240-251. doi: 10.1038/sj.bjp.0707584
- Capuron, L., & Miller, A. H. (2011). Immune system to brain signaling: neuropsychopharmacological implications. *Pharmacology and Therapeutics*, *130*(2), 226-238. doi: 10.1016/j.pharmthera.2011.01.014
- Caraci, F., Copani, A., Nicoletti, F., & Drago, F. (2010). Depression and Alzheimer's disease: neurobiological links and common pharmacological targets. *European Journal of Pharmacology*, *626*(1), 64-71. doi: 10.1016/j.ejphar.2009.10.022
- Chauveau, F., Boutin, H., Van Camp, N., Dolle, F., & Tavitian, B. (2008). Nuclear imaging of neuroinflammation: a comprehensive review of [11C]PK11195 challengers. *European Journal of Nuclear Medicine and Molecular Imaging*, *35*(12), 2304-2319. doi: 10.1007/s00259-008-0908-9
- Dahl, J., Ormstad, H., Aass, H. C., Malt, U. F., Bendz, L. T., Sandvik, L., . . . Andreassen, O. A. (2014). The plasma levels of various cytokines are increased during ongoing depression and are reduced to normal levels after recovery. *Psychoneuroendocrinology*, *45*, 77-86. doi: 10.1016/j.psyneuen.2014.03.019
- Eyre, H., & Baune, B. T. (2012). Neuroplastic changes in depression: a role for the immune system. *Psychoneuroendocrinology*, *37*(9), 1397-1416. doi: 10.1016/j.psyneuen.2012.03.019
- Farooqui, A. A., Horrocks, L. A., & Farooqui, T. (2007). Modulation of inflammation in brain: a matter of fat. *Journal of Neurochemistry*, *101*(3), 577-599. doi: 10.1111/j.1471-4159.2006.04371.x
- Fava, M. (2003). Diagnosis and definition of treatment-resistant depression. *Biological Psychiatry*, *53*(8), 649-659.

- Gaemperli, O., Shalhoub, J., Owen, D. R., Lamare, F., Johansson, S., Fouladi, N., . . . Camici, P. G. (2012). Imaging intraplaque inflammation in carotid atherosclerosis with <sup>11</sup>C-PK11195 positron emission tomography/computed tomography. *European Heart Journal*, *33*(15), 1902-1910. doi: 10.1093/eurheartj/ehr367
- Gelenberg, A. J., Thase, M. E., Meyer, R. E., Goodwin, F. K., Katz, M. M., Kraemer, H. C., . . . Rosenbaum, J. F. (2008). The history and current state of antidepressant clinical trial design: a call to action for proof-of-concept studies. *Journal of Clinical Psychiatry*, *69*(10), 1513-1528.
- Goodkind, M., Eickhoff, S. B., Oathes, D. J., Jiang, Y., Chang, A., Jones-Hagata, L. B., . . . Etkin, A. (2015). Identification of a common neurobiological substrate for mental illness. *JAMA Psychiatry*, *72*(4), 305-315. doi: 10.1001/jamapsychiatry.2014.2206
- Haapakoski, R., Ebmeier, K. P., Alenius, H., & Kivimaki, M. (2016). Innate and adaptive immunity in the development of depression: An update on current knowledge and technological advances. *Progress in Neuropsychopharmacology & Biological Psychiatry*, *66*, 63-72. doi: 10.1016/j.pnpbp.2015.11.012
- Hannestad, J., DellaGioia, N., Gallezot, J. D., Lim, K., Nabulsi, N., Esterlis, I., . . . Carson, R. E. (2013). The neuroinflammation marker translocator protein is not elevated in individuals with mild-to-moderate depression: a [<sup>11</sup>C]PBR28 PET study. *Brain, Behavior, and Immunity*, *33*, 131-138. doi: 10.1016/j.bbi.2013.06.010
- Hawkey, C. J., & Yeomans, N. D. (1999). The treatment and prophylaxis of nonsteroidal anti-inflammatory drug (NSAID)-associated ulcers and erosions. *The Canadian Journal of Gastroenterology & Hepatology*, *13*(4), 291, 295.
- Howren, M. B., Lamkin, D. M., & Suls, J. (2009). Associations of depression with C-reactive protein, IL-1, and IL-6: a meta-analysis. *Psychosomatic Medicine*, *71*(2), 171-186. doi: 10.1097/PSY.0b013e3181907c1b
- Jacobs, A. H., Tavitian, B., & INMiND Consortium (2012). Noninvasive molecular imaging of neuroinflammation. *Journal of Cerebral Blood Flow and Metabolism*, *32*(7), 1393-1415. doi: 10.1038/jcbfm.2012.53
- Katori, M., & Majima, M. (2000). Cyclooxygenase-2: its rich diversity of roles and possible application of its selective inhibitors. *Inflammation Research*, *49*(8), 367-392.
- Kohler, O., Krogh, J., Mors, O., & Benros, M. E. (2015). Inflammation in Depression and the Potential for Anti-Inflammatory Treatment. *Current Neuropharmacology*, [epub ahead of print].
- Krishnadas, R., & Cavanagh, J. (2012). Depression: an inflammatory illness? *Journal of Neurology, Neurosurgery & Psychiatry*, *83*(5), 495-502. doi: 10.1136/jnnp-2011-301779
- Krishnan, R., Cella, D., Leonardi, C., Papp, K., Gottlieb, A. B., Dunn, M., . . . Jahreis, A. (2007). Effects of etanercept therapy on fatigue and symptoms of depression in subjects treated for moderate to severe plaque psoriasis for up to 96 weeks. *British Journal of Dermatology*, *157*(6), 1275-1277. doi: 10.1111/j.1365-2133.2007.08205.x
- Lanquillon, S., Krieg, J. C., Bening-Abu-Shach, U., & Vedder, H. (2000). Cytokine production and treatment response in major depressive disorder. *Neuropsychopharmacology*, *22*(4), 370-379. doi: 10.1016/S0893-133X(99)00134-7
- Lavisse, S., Guillermier, M., Herard, A. S., Petit, F., Delahaye, M., Van Camp, N., . . . Escartin, C.

- (2012). Reactive astrocytes overexpress TSPO and are detected by TSPO positron emission tomography imaging. *Journal of Neuroscience*, 32(32), 10809-10818. doi: 10.1523/JNEUROSCI.1487-12.2012
- Lee, T. S., Quek, S. Y., & Krishnan, K. R. (2014). Molecular imaging for depressive disorders. *American Journal of Neuroradiology*, 35(6 Suppl), S44-54. doi: 10.3174/ajnr.A3965
- Maes, M. (2011). Depression is an inflammatory disease, but cell-mediated immune activation is the key component of depression. *Progress in Neuropsychopharmacology & Biological Psychiatry*, 35(3), 664-675. doi: 10.1016/j.pnpbp.2010.06.014
- Maes, M., Berk, M., Goehler, L., Song, C., Anderson, G., Galecki, P., & Leonard, B. (2012). Depression and sickness behavior are Janus-faced responses to shared inflammatory pathways. *BMC Medicine*, 10, 66. doi: 10.1186/1741-7015-10-66
- Maes, M., Meltzer, H. Y., Bosmans, E., Bergmans, R., Vandoolaeghe, E., Ranjan, R., & Desnyder, R. (1995). Increased plasma concentrations of interleukin-6, soluble interleukin-6, soluble interleukin-2 and transferrin receptor in major depression. *Journal of Affective Disorders*, 34(4), 301-309.
- Maes, M., Song, C., Lin, A. H., Bonaccorso, S., Kenis, G., De Jongh, R., . . . Scharpe, S. (1999). Negative immunoregulatory effects of antidepressants: inhibition of interferon-gamma and stimulation of interleukin-10 secretion. *Neuropsychopharmacology*, 20(4), 370-379. doi: 10.1016/S0893-133X(98)00088-8
- Maes, M., Song, C., Lin, A. H., Pioli, R., Kenis, G., Kubera, M., & Bosmans, E. (1999). In vitro immunoregulatory effects of lithium in healthy volunteers. *Psychopharmacology (Berl)*, 143(4), 401-407.
- Mankoff, D. A. (2007). A definition of molecular imaging. *Journal of Nuclear Medicine*, 48(6), 18N, 21N.
- Miller, A. H., Maletic, V., & Raison, C. L. (2009). Inflammation and its discontents: the role of cytokines in the pathophysiology of major depression. *Biological Psychiatry*, 65(9), 732-741. doi: 10.1016/j.biopsych.2008.11.029
- Minghetti, L. (2004). Cyclooxygenase-2 (COX-2) in inflammatory and degenerative brain diseases. *Journal of Neuropathology & Experimental Neurology*, 63(9), 901-910.
- Money, K. M., Olah, Z., Korade, Z., Garbett, K. A., Shelton, R. C., & Mirnics, K. (2016). An altered peripheral IL6 response in major depressive disorder. *Neurobiology of Disease*, 89, 46-54. doi: 10.1016/j.nbd.2016.01.015
- Muller, N., Schwarz, M. J., Dehning, S., Douhe, A., Cerovecki, A., Goldstein-Muller, B., . . . Riedel, M. (2006). The cyclooxygenase-2 inhibitor celecoxib has therapeutic effects in major depression: results of a double-blind, randomized, placebo controlled, add-on pilot study to reboxetine. *Molecular Psychiatry*, 11(7), 680-684. doi: 10.1038/sj.mp.4001805
- O'Leary, O. F., Dinan, T. G., & Cryan, J. F. (2015). Faster, better, stronger: towards new antidepressant therapeutic strategies. *European Journal of Pharmacology*, 753, 32-50. doi: 10.1016/j.ejphar.2014.07.046
- Ory, D., Celen, S., Verbruggen, A., & Bormans, G. (2014). PET radioligands for in vivo visualization of neuroinflammation. *Current Pharmaceutical Design*, 20(37), 5897-5913.
- Pulli, B., & Chen, J. W. (2014). Imaging Neuroinflammation - from Bench to Bedside. *Journal of Clinical & Cellular Immunology*, 5. doi: 10.4172/2155-9899.1000226

- Raju, T. N. (1998). The Nobel chronicles. 1927: Julius Wagner-Jauregg (1857-1940). *Lancet*, 352(9141), 1714. doi: 10.1001/jamapsychiatry.2014.2427
- Reichenberg, A., Yirmiya, R., Schuld, A., Kraus, T., Haack, M., Morag, A., & Pollmacher, T. (2001). Cytokine-associated emotional and cognitive disturbances in humans. *Archives of General Psychiatry*, 58(5), 445-452.
- Rosenblat, J. D., Cha, D. S., Mansur, R. B., & McIntyre, R. S. (2014). Inflamed moods: a review of the interactions between inflammation and mood disorders. *Progress in Neuropsychopharmacology & Biological Psychiatry*, 53, 23-34. doi: 10.1016/j.pnpbp.2014.01.013
- Rupprecht, R., Papadopoulos, V., Rammes, G., Baghai, T. C., Fan, J., Akula, N., . . . Schumacher, M. (2010). Translocator protein (18 kDa) (TSPO) as a therapeutic target for neurological and psychiatric disorders. *Nature Reviews Drug Discovery*, 9(12), 971-988. doi: 10.1038/nrd3295
- Rush, A. J., Trivedi, M. H., Wisniewski, S. R., Nierenberg, A. A., Stewart, J. W., Warden, D., . . . Fava, M. (2006). Acute and longer-term outcomes in depressed outpatients requiring one or several treatment steps: a STAR\*D report. *American Journal of Psychiatry*, 163(11), 1905-1917. doi: 10.1176/ajp.2006.163.11.1905
- Schafer, D. P., Lehrman, E. K., Kautzman, A. G., Koyama, R., Mardinly, A. R., Yamasaki, R., . . . Stevens, B. (2012). Microglia sculpt postnatal neural circuits in an activity and complement-dependent manner. *Neuron*, 74(4), 691-705. doi: 10.1016/j.neuron.2012.03.026
- Setiawan, E., Wilson, A. A., Mizrahi, R., Rusjan, P. M., Miler, L., Rajkowska, G., . . . Meyer, J. H. (2015). Role of translocator protein density, a marker of neuroinflammation, in the brain during major depressive episodes. *JAMA Psychiatry*, 72(3), 268-275. doi: 10.1001/jamapsychiatry.2014.2427
- Sierra, A., Encinas, J. M., Deudero, J. J., Chancey, J. H., Enikolopov, G., Overstreet-Wadiche, L. S., . . . Maletic-Savatic, M. (2010). Microglia shape adult hippocampal neurogenesis through apoptosis-coupled phagocytosis. *Cell Stem Cell*, 7(4), 483-495. doi: 10.1016/j.stem.2010.08.014
- Smith, J. A., Das, A., Ray, S. K., & Banik, N. L. (2012). Role of pro-inflammatory cytokines released from microglia in neurodegenerative diseases. *Brain Research Bulletin*, 87(1), 10-20. doi: 10.1016/j.brainresbull.2011.10.004
- Smith, R. S. (1991). The macrophage theory of depression. *Medical Hypotheses*, 35(4), 298-306.
- Song, C., & Zhao, S. (2007). Omega-3 fatty acid eicosapentaenoic acid. A new treatment for psychiatric and neurodegenerative diseases: a review of clinical investigations. *Expert Opinion on Investigational Drugs*, 16(10), 1627-1638. doi: 10.1517/13543784.16.10.1627
- Streit, W. J., Mrak, R. E., & Griffin, W. S. (2004). Microglia and neuroinflammation: a pathological perspective. *Journal of Neuroinflammation*, 1(1), 14. doi: 10.1186/1742-2094-1-14
- Szuster-Ciesielska, A., Tustanowska-Stachura, A., Slotwinska, M., Marmurowska-Michalowska, H., & Kandfer-Szerszen, M. (2003). In vitro immunoregulatory effects of antidepressants in healthy volunteers. *Polish Journal of Pharmacology*, 55(3), 353-362.
- Wager-Smith, K., & Markou, A. (2011). Depression: a repair response to stress-induced neuronal microdamage that can grade into a chronic neuroinflammatory condition? *Neuroscience & Biobehavioral Reviews*, 35(3), 742-764. doi: 10.1016/j.neubiorev.2010.09.010

- Wilson, A. A., Garcia, A., Parkes, J., McCormick, P., Stephenson, K. A., Houle, S., & Vasdev, N. (2008). Radiosynthesis and initial evaluation of [18F]-FEPPA for PET imaging of peripheral benzodiazepine receptors. *Nuclear Medicine and Biology*, 35(3), 305-314. doi: 10.1016/j.nucmedbio.2007.12.009
- Wright, C. E., Strike, P. C., Brydon, L., & Steptoe, A. (2005). Acute inflammation and negative mood: mediation by cytokine activation. *Brain, Behavior, and Immunity*, 19(4), 345-350. doi: 10.1016/j.bbi.2004.10.003
- Wu, C., Li, F., Niu, G., & Chen, X. (2013). PET imaging of inflammation biomarkers. *Theranostics*, 3(7), 448-466. doi: 10.7150/thno.6592
- Xia, Z., DePierre, J. W., & Nassberger, L. (1996). Tricyclic antidepressants inhibit IL-6, IL-1 beta and TNF-alpha release in human blood monocytes and IL-2 and interferon-gamma in T cells. *Immunopharmacology*, 34(1), 27-37.





# *Hybrid Imaging: A Proof-of-Concept Attempt at Understanding Neuroinflammation in Depression*

Nicole M. Marlatt, PhD<sup>1</sup>, Amer M. Burhan, MBChB, MSc., FRCPC<sup>2</sup>, Lena Palaniyappan, MBBS, PhD<sup>3</sup>

1. Project Manager, Mental Health Research, St. Joseph's Health Care London, Parkwood Institute, London, ON
2. Geriatric Neuropsychiatrist and Physician Clinical Lead for Therapeutic Brain Stimulation, St. Joseph's Health Care London, Parkwood Institute, London, ON
3. Psychiatrist and Director of the Prevention and Early Intervention Program in Psychosis (PEPP), London Health Sciences Centre, Victoria Hospital, London, ON

**Key words:** Neuroimaging, Humans, Inflammation-Associated Depression, Major Depressive Disorders, Hybrid Imaging, Molecular Imaging, Treatment-Resistant Depression, Positron Emission Tomography, Magnetic Resonance Imaging, Proof-of-Concept

## ABSTRACT

*Inflammation of the central nervous system has been associated with and thought to contribute to neuropsychiatric syndromes and many other human disorders such as multiple sclerosis and Parkinson's disease. Depression, for example, is now seen as an inflammatory disease where abnormal activation of microglial cells (inflammatory cells) produce long-lasting depression-like behaviour. However, the underlying molecular mechanism of neuroinflammation and how it exactly contributes to these disorders is still largely unknown. An emerging integrated technology called hybrid imaging, has the potential to combine functional, molecular and structural imaging in vivo and could provide a significant amount of information about the inflammation processes in the human brain. Emerging molecular imaging techniques may be the most informative, non-invasive technique currently available for the characterization of neuroinflammation. In this brief review, an overview of inflammation and its association with depression is discussed, along with an overview of the utility of hybrid imaging. This imaging technique and its use in proof-of-concept type studies regarding neuroinflammation pathophysiology is presented with an emphasis on its utility in providing surrogate endpoints for the identification and treatment of neuroinflammation in depression.*

## Background Highlights

Inflammation of the central nervous system (neuroinflammation) has been associated with the pathophysiology of many human disorders, including Parkinson's disease, multiple sclerosis, amyotrophic lateral sclerosis and neuropsychiatric

illnesses such as schizophrenia and major depressive disorders. As a result, research focused on developing meaningful methods to identify, monitor and characterize neuroinflammation has gained significant interest in the last decade. Molecular neuroimaging methods, in particular,

have significantly advanced to a point where they may arguably be one of the most informative, non-invasive techniques available today for the characterization of neuroinflammation. In this brief review, an overview of a novel imaging modality called “hybrid imaging” is described. Hybrid (multimodal or fusion) imaging is an integrated technology that combines functional/molecular imaging and structure imaging technologies. It has the potential to reveal molecular processes *in vivo*, while simultaneously depicting anatomic location or function, thereby providing many benefits to the pathophysiological aspects of many diseases affecting the central nervous system. This imaging technique and its utility in proof-of-concept type studies regarding neuroinflammation pathophysiology is presented here in the context of what can be discovered about the leading mental health disorder and cause of disability worldwide - *depression*.

### **Hypotheses of Depression**

Depression is a significant contributor to the global burden of disease and affects approximately 350 million people worldwide from all ethnic backgrounds and communities (<http://www.who.int/mediacentre/factsheets/fs369/en/>). Depression falls under the category of affective disorders: a set of psychiatric illnesses that are also referred to as mood disorders. The main types of affective disorders are unipolar depression, depressive disorders with anxious distress, and bipolar disorders. Symptoms vary by individual, but they almost always affect mood. Unfortunately, the symptom-based diagnostic approach used for affective disorders (American Psychiatric Association, 2013) is an obstacle in diagnosis and treatment, as anxiety disorders have tremendous overlap and are commonly comorbid with major depressive disorders (Hasler, Drevets, Manji, & Charney, 2004). Having distinct molecular and mechanistic underpinnings further complicates these disorders and has hindered the development of targeted pharmacotherapy treatments (Goodwin, 2015). In addition, clinical depression is

multifactorial and precipitated in patients with a history of abuse, substance disorders, major illnesses and genetic predispositions. The complexity of depression is now evident and has led our understanding away from a simple monoamine deficiency in the brain.

It has been over half a century since the *Monoamine Hypothesis for Depression* was proposed, declaring that patients with depression have depleted concentrations of central monoamines such as serotonin, norepinephrine, and dopamine (Bunney & Davis, 1965; Delgado, 2000; Hirschfeld, 2000; Schildkraut, 1965). However, after fifty-plus years of treating depression with antidepressant drugs targeting monoamines, it is now clear that monoamine depletion is not the entire story, as this aspect of the syndrome likely plays a modulator-type role that may influence other neurobiological systems (Charney, 1998). There are a number of limitations to the monoamine hypothesis, including the fact that direct monoamine depletion in healthy subjects, for example, does not produce depressive symptoms (Salomon, Miller, Krystal, Heninger, & Charney, 1997). In addition, monoaminergic antidepressant drugs act quickly to increase monoamine transmission/production, though it usually takes an average of 4-12 weeks for these drugs to illustrate mood-enhancing properties (Ruhe, Mason, & Schene, 2007; Schulberg, Katon, Simon, & Rush, 1998; Uher et al., 2011). Further, a sizeable portion (around 40%) of depressed patients fail to respond adequately to conventional antidepressants (i.e. those with the monoamine hypothesis as their theoretical basis) (Rush et al., 2006). To overcome these defects with the monoamine hypothesis, a number of alternative hypotheses have been proposed, including the glutamate (Sanacora, Treccani, & Popoli, 2012), neurogenic (Petrik, Lagace, & Eisch, 2012), epigenetic (Nestler, 2014), cortisol hypersecretion (Duval et al., 2006) and inflammatory hypotheses (Madeeh Hashmi, Awais Aftab, Mazhar, Umair, & Butt, 2013; Miller & Raison, 2016). Taken together, the current

understanding of depression is that it is multifactorial and heterogeneous in nature, with many genetic and environmental factors contributing to the onset of the complex syndrome. A better understanding of depression at the molecular level is now needed to uncover the mechanistic framework within which therapeutic targets and early diagnostics can be enriched with clarity and precision.

Here we will provide an overview of how hybrid imaging, a novel advancement to neuroimaging technology, can help develop a deeper understanding of the molecular complexities of depression. We frame this short imaging review with one proof-of-concept study in mind, the real unknown at this point: Is neuroinflammation a protective by-product of depression or is it exaggerated to a point of neurotoxicity?

### ***The Role of Inflammation in Depression***

The association between inflammation and depression has been well documented in the literature. The evidence that depression is affiliated with a subtle but chronic inflammatory process comes from several observations. Major Depressive Disorder (MDD), for example, even in the absence of a medical illness, is consistently associated with raised peripheral inflammatory markers (Dowlati et al., 2010). Further, the concentrations of these inflammatory markers (interleukins) reduce with successful treatment of depression (Hannestad, DellaGioia, & Bloch, 2011). Inflammatory medical conditions are also associated with greater rates of major depression. In fact, depression is a major cause of disability in patients with chronic and recurrent inflammatory responses such as rheumatoid arthritis, chronic hepatitis, and others (Krishnadas & Cavanagh, 2012; Margaretten, Julian, Katz, & Yelin, 2011). In line with this, is the observation that the rates of depression become much higher when the inflammatory activity or tissue damage directly involves the brain e.g. multiple sclerosis, stroke and Parkinson's disease (Krishnadas & Cavanagh, 2012). Patients, who

have no history of depression, when treated with inflammation-mediating agents such as interferons, develop major depressive episodes. This notion is now so well established that many clinicians consider prophylactic antidepressants when starting interferon therapy (Ehret & Sobieraj, 2014).

Depression is now seen as an inflammatory microglial disease (Yirmiya, Rimmerman, & Reshef, 2015), where abnormal activation of microglial cells (inflammatory cells) in animal models produce long-lasting depression-like behaviour. Minocycline, an agent that reverses aberrant microglial activity due to its anti-inflammatory properties (Frick, Williams, & Pittenger, 2013), results in an antidepressant-like effect in a well-established animal model of depression (Arakawa et al., 2012). Therefore, in our progression towards understanding depression's pathophysiology, we see factors that point to an association between depression and inflammation, where depression can activate proinflammatory pathways, antidepressants can decrease the inflammatory response and inhibition of inflammatory pathways can improve mood. Exploring these factors and a possible pathway linking inflammation and neurobiological changes found in depression allows us to look closer at the possible integration of the inflammatory process and depressive symptoms.

### ***Molecular Aspects of Depression***

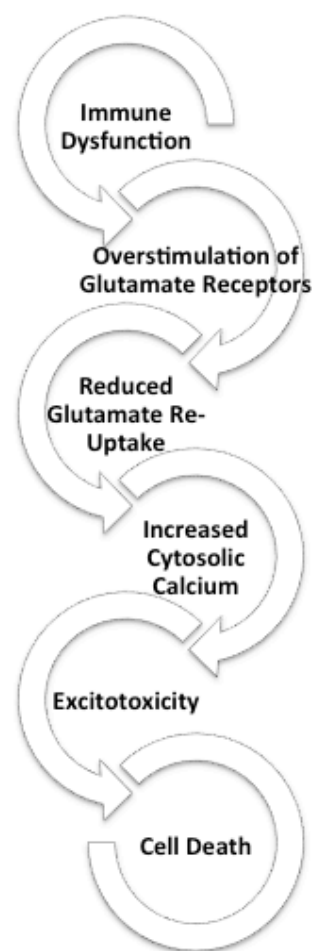
Depression appears to be the prototypical neuropsychiatric illness that is associated with an inflammatory process. Emerging evidence suggests that several other brain disorders could be linked to brain tissue inflammation. Chronic but subtle neuroinflammation seems to be associated with a broad spectrum of neurodegenerative diseases of aging, such as Alzheimer's disease, Parkinson's disease, amyotrophic lateral sclerosis, several tauopathies, epilepsy (Tansey, 2010), and with relapsing and remitting psychiatric illnesses such as schizophrenia (Bloomfield et al., 2016).

With respect to mental illnesses such as depression and schizophrenia, the role of neurotransmitter abnormalities is well established. While brain's monoamine system (serotonin, norepinephrine and dopamine) have been the major focus of study in these disorders, of late, the role of abnormalities in glutamate, the most common excitatory neurotransmitter in the human brain, in neuropsychiatric disorders is now well appreciated. One of the most exciting recent developments in this regard is the discovery that ketamine and related agents, which predominantly act on glutamatergic systems, have remarkably rapid antidepressant properties with effects often seen within a few hours after intravenous administration (Zarate et al., 2010). This rapidity is in stark contrast to the several weeks of treatments required when using monoamine-based antidepressants.

The emergence of international focus on glutamatergic treatments for mental disorders is highly relevant to the role of inflammation in these disorders. Specifically, within the brain's cellular environment, brain-resident macrophages (e.g. microglia) are critical in mediating immune responses and inflammation, and they work in conjunction with cells such as astrocytes and oligodendrocytes. This glial system enables the clearance (uptake) of the stimulatory neurotransmitter glutamate, in the absence of which overstimulation and consequent tissue damage ensues. Unchecked excess of glutamate increases intracellular calcium, which triggers a cascade of cellular destruction (Mark et al., 2001) (Figure 1). If this process occurs in a recurrent or chronic manner, albeit subtle in intensity, this may result in tissue loss (grey matter reduction). Distributed reduction of grey matter is a consistent observation in many psychiatric and neurodegenerative disorders including depression, schizophrenia and dementia. In many psychiatric disorders including depression and schizophrenia, such reduction is concentrated around the insula and anterior cingulate cortex (Palaniyappan & Liddle, 2012; Palaniyappan, White, & Liddle, 2012, 2015).

Interestingly, these brain regions are linked to the 'sickness response' seen during systemic inflammation in humans (Hannestad et al., 2011), and mediate the fatigue symptoms seen following the inflammatory response to typhoid vaccination (Harrison et al., 2009). This raises the possibility that inflammation is exaggerated and becomes pathological, damaging these regions, possibly via excess glutamate. The over activation of receptors for the excitatory neurotransmitter glutamate, such as the N-methyl-D-aspartate (NMDA) receptor leads to neuron damage and death and is known as the pathological process called 'excitotoxicity' (Figure 1).

**Figure 1. Immune dysfunction leads to a cascade of events that can lead to excitotoxicity in the brain causing neuronal death and grey matter loss.**



Neuroinflammation involves several molecular and cellular mechanisms that are designed to mitigate harmful events and repair damage. *In vivo* molecular imaging has associated inflammation with schizophrenia (Pasternak, Kubicki, & Shenton, 2016; Pasternak, Westin, Dahlben, Bouix, & Kubicki, 2015) and other psychiatric disorders (Alexopoulos & Morimoto, 2011). In order to establish the direct role of brain inflammation in causing tissue damage relevant to depression and other disorders, we need to study (1) the microglia that are participating in the brain's inflammatory response (2) glutamatergic concentrations in the vicinity of regions showing microglial activity. Importantly, simultaneous imaging of these two aspects is crucial to confidently demonstrate or dismiss the relationship between inflammation and tissue damage via excitotoxicity. This requires using a hybrid imaging scanner to simultaneously measure molecular glutamate concentrations and target the cells (microglia) that release glutamate in structural brain regions of interest.

### Hybrid Imaging

Hybrid (multimodal or fusion) imaging is an integrated technology that combines functional/molecular imaging and structural imaging technologies (Hricak et al., 2010). The strengths of each modality synergistically complement each other to create a new and more powerful tool, overcoming their stand-alone limitations. Many hybrid imaging platforms are capable of true simultaneous data acquisition and therefore leads to an increased level of confidence with which disease abnormalities can be localized (Hicks, Lau, & Binns, 2007). The potential of hybrid imaging to reveal molecular processes *in vivo*, while simultaneously depicting their anatomic location, provides many benefits to many different disciplines. Specifically, the generalized benefits include increased diagnostic accuracy, reduced radiation exposure, advancements to individualized medicine (or molecularly targeted medicine) and precise monitoring of interventional procedures. These benefits are useful in oncology, cardiology,

neurology, psychiatry and pharmacology for facilitating diagnosis, staging the disease, defining treatment plans, and monitoring treatment response; such crucial outcomes cannot be provided by anatomical imaging techniques alone, i.e. Magnetic Resonance (MR) imaging or computed tomography (CT). Furthermore, functional and metabolic changes can and do occur without a corresponding anatomical abnormality. Hence, hybrid imaging will play a major role in advancing our understanding of diseases and theranostics for years to come.

There are many hybrid imaging modalities currently available: Positron Emission Spectroscopy (PET)/CT; Single-photon emission computed tomography (SPECT)/CT; MR/PET; MR/SPECT; ultrasound/MR; ultrasound/CT; MR/CT and two different ways in which imaging modalities are combined (Townsend, 2008). The software fusion approach aligns two image sets post-hoc after being acquired on different scanners at different times (reviewed by (Slomka, 2004)). However, the hardware fusion method combines instrumentation for two imaging modalities and acquires both images within the same reference frame. This is more novel than the software approach. It is ground-breaking in medical imaging, enabling co-registered structural and functional information of the system to be obtained in a single scan, simultaneously. There has been a significant amount of focus on hardware fusion hybrid imaging modalities ever since tomographic imaging of function/metabolism (PET) was combined with anatomical localization (CT) and voted "Medical Invention of the Year" in 2000 by Time magazine (Time December 4, 2000).

### ***Hybrid PET/CT: Development and Utility in Neuroimaging***

Prior to the commercial introduction of hybrid PET/CT in 2001, individual PET scanners were marketed primarily for research. However, the clinical acceptance of this technology was quick to occur, with oncology being the first discipline to

see the potential of PET/CT and accept its clinical capability in the early 2000s (Beyer et al., 2000). The adoption of PET/CT as a clinical tool, continued to grow so rapidly that it eventually was no longer commercially viable to market stand-alone PET systems. In fact, more than 95% of all PET scanners sold in 2004 were hybrid PET/CT scanners and by 2006, practically all stand-alone PET scanners had been replaced by PET/CT scanners.

PET relies on exogenous synthetic radiolabeled molecules being injected into the bloodstream that have an affinity component and a signalling component (Hricak et al., 2010). The most widely used tracer in oncology and neurology, to date, is the PET imaging glucose analog  $^{18}\text{F}$ -fluorodeoxyglucose ( $^{18}\text{F}$ -FDG). In neurology, the grey matter of the brain preferentially uses glucose as a metabolic substrate and both increased and decreased metabolism is used to evaluate neurological abnormalities.

It may appear that PET is limited by the development of safe radiolabeled tracers. However, novel PET tracers are developed continuously and now exist for many metabolic substrates, hypoxia agents, neurotransmitters, and drugs. The utility of these tracers can be highlighted by certain PET studies into pre-symptomatic (or pre-clinical) Alzheimer's Disease (Mori et al., 2012), which have been proven to detect dementia earlier than any other imaging modality or neurological test (Bourgeat et al., 2010; Mori et al., 2012; Rowe et al., 2008). Hence, PET tracers are likely to change the way in which disease processes are understood and treated. However, the major drawback to using PET/CT imaging routinely, is patient exposure to both external radiation from the CT scan and internal radiation from the injected tracer (Brix & Beyer, 2005). This ultimately limits the ability to do repeat PET studies using different PET tracers, especially in healthy controls, and has generated a greater interest in non-ionizing techniques such as MR imaging.

### ***Hybrid PET/MR: Development and Utility in Neuroimaging***

MR imaging is a much more complex and versatile modality, compared to CT, in terms of the different characteristics of human tissue it is able to measure. MR imaging reveals structure and function through atomic (primarily protons) interactions with a strong magnetic field. The primary method of revealing function by MR imaging is the utilization of the blood-oxygen-level dependent (BOLD) signal (Huettel, Song, & McCarthy, 2009). This specialized brain scan has the ability to map neural activity by imaging the hemodynamic response (blood flow) that is directly correlated to energy use by brain cells (Logothetis & Pfeuffer, 2004). Therefore, the desire to combine this useful modality of brain mapping with PET imaging has been long-standing. PET/MR was in the pre-clinical stage, until 2006 when the first simultaneous PET/MR imaging of the human brain took place (Schlemmer et al., 2008) and the first commercially marketed PET/MR instrument was available by 2010.

MR imaging offers better contrast among soft tissues as well as functional-imaging capabilities, compared to CT. For example, PET/MR data acquisition is simultaneous, versus sequentially collected in PET/CT imaging. This gives PET/MR essentially perfect temporal correlation of dynamically acquired data sets from both modalities (Pichler, Judenhofer, & Pfannenber, 2008). The excellent soft-tissue contrast and the fact that it reduces the effective radiation dose are additional advantages of MR for pre-clinical research studies and in clinical applications (Brix & Beyer, 2005; Disselhorst, Bezrukov, Kolb, Parl, & Pichler, 2014).

### ***Current Imaging Research of Neuroinflammation in Depression***

Heightened microglial activity in depression has now been documented in PET studies (Setiawan et al., 2015). Using  $^{18}\text{F}$ -FEPPA, Setiawan et al. recently reported that microglia transporter protein

(TSPO) volume of distribution was significantly elevated by a magnitude of 26% in the prefrontal cortex, 32% in the anterior cingulate cortex (ACC), and 33% in the insula of patients with major depressive episodes. In particular, the greater TSPO volume of distribution in the ACC correlated with greater depression severity.

Several recent editorials have indicated that the study of neuroinflammation and tissue damage is likely to be the most promising pathways for new drug development in depression (Friedrich, 2014; Maes et al., 2011). A global consortia of academics that potentially influence drug discovery have also highlighted this field as the central theme of recent conventions (<http://www.cinp.org/2015-thematic-meeting-dublin/>).

Currently, there are 5 established groups (in addition to many smaller, more recently constituted teams) who are actively pursuing PET studies of neuroinflammation in mental disorders. The Centre for Addictions and Mental Health and the University of Toronto are leaders in this field, with more recent discoveries emerging from Yale University. British multi-site teams that include Manchester, Nottingham and Cardiff are using both PET and glutamate imaging in distinct subgroups, but simultaneous combined PET/MR hybrid imaging has not yet been attempted. Furthermore, both at Yale and in Nottingham,  $^{13}\text{C}$ -Magnetic Resonance Spectroscopy (MRS) is being used for glutamate, which cannot provide whole-brain data, and is very expensive. Currently, all of these groups are making incremental progress towards linking glutamate and neuroinflammation in mental disorders, but the evidence generated by these efforts are, at best, only circumstantial. In this context, what is needed is a proof-of-concept study that can directly connect neuroinflammation with glutamate levels and specifically elicit whether the levels are consistent with excitotoxicity. The novel hybrid imaging PET/MR technique will help move this focus of research forward.

### ***Using Hybrid Imaging for a Proof-of-Concept Medical Breakthrough***

Proof-of-concept (PoC) is a frequently used term that is often incorrectly interchanged with words such as prototype, pilot or proof-of-principle. However, all of these terms mean something very different and they all serve different purposes in the pursuit of scientific discovery and medical breakthroughs. PoC studies test a discrete design, idea, or assumption. To be deliberate, a PoC should clearly state what it is to be proven and to what degree. For example, it may not be good enough to identify a specific marker of neuroinflammation in depression (e.g activated microglia); it may need to be a specific test with a level of performance and reliability. Certain test conditions are key.

Several pharmaceutical companies are currently developing compounds that can target glutamatergic damage in persistent and severe mental illnesses such as depression and schizophrenia. However, there is a lack of minimally invasive surrogate markers that can serve as endpoints of physiological response in phase 2 trials in human volunteers. By measuring glutamatergic concentration in brain regions that show microglial activation, quantification of treatment-induced changes becomes feasible. This aspect could be disseminated through a hybrid imaging study design that utilizes PET tracer [ $^{18}\text{F}$ ]-FEPPA and MR imaging techniques that simultaneously measure full brain glutamate levels. Microglial activation in inflamed brain regions can be quantified *in vivo* using PET ligands that bind to TSPO expressed on the cells mitochondrial membrane (Ory, Celen, Verbruggen, & Bormans, 2014). Injecting immune activating substances such as lipopolysaccharide acutely increases the expression of this protein in human brains, as observed using PET imaging (Sandiego et al., 2015). This protein has been mostly studied using a radioligand called [ $^{11}\text{C}$ ]PK11195 which has low brain penetration and a weaker affinity for TSPO compared to the second generation ligands such as [ $^{18}\text{F}$ ]-FEPPA (Ory et al., 2014). [ $^{18}\text{F}$ ]-FEPPA was

originally developed for human studies at the Centre for Addictions and Mental Health, Toronto, and it is now being used at additional institutes for use in clinical research with tertiary mental health care patients.

One of the challenges in quantifying concentrations of glutamate in brain tissue is the need to choose a specific portion of the brain to obtain magnetic resonance spectrum. This 'region-of-interest' based method is not useful to study the entire brain to collocate microglial activation and glutamate excess. A technique called glutamate Chemical Exchange Saturation Transfer (gluCEST), which has been specifically developed using 7T scanners (Cai et al., 2012; Cai et al., 2013), has demonstrated a more than 700 times higher sensitivity to glutamate than traditional MRS (Cai et al., 2013). Where MRS could examine cuboid brain regions of interest with sizes of 1-8cm, GluCEST can examine the whole brain with 1-2mm resolution. The fast exchange rate of glutamate amine protons is most conducive for imaging at higher field strength (7 Tesla) than 3T, but meaningful signals to quantify glutamate can be obtained by increasing the number of data points used for signal averaging, and this has recently been demonstrated in mental disorders (Theberge et al., 2002; Theberge et al., 2007).

Distributed glutamate abnormalities and a 'fingerprint' of brain inflammation (i.e. microglia activation) can be simultaneously measured with hybrid imaging scans. This PoC study will provide a method of studying inflammation related excitotoxicity in depression, and observe a relationship between glutamate levels and microglial activity in brain regions relevant for the pathophysiology of depression. This will allow researchers to move away from only knowing that inflammation is associated with depression to knowing whether it is neurotoxic, or merely a protective by-product of the disease itself.

### ***Designing Proof-of-Concept Studies***

The most important aspect of PoC studies for revealing the underlying molecular aspects of inflammation-associated depression is in selecting the most appropriate patient population for the study. Homogeneity of the sample becomes very important to the question being tested. For example, to test if and when inflammation becomes neurotoxic would involve comparisons between a first-episode depressed population and those with chronic depression. Longitudinal studies could also be used to correlate microglia activity, glutamate levels and clinical measures of depression. For testing the utility of the technique (combined FEPPA and GluCEST) in measuring neuroinflammation, a comparison between healthy controls and those highly likely to have inflammation-associated depression would be appropriate. A typical neuroinflammation sample would include only those with MDD who have failed multiple treatment trials and are considered to have treatment-resistant depression, as a significant percentage of these patients exhibit increased markers of inflammation (Raison, Felger, & Miller, 2013). Additional screening may exclude those currently taking antidepressants because of the immunoregulatory activities of these drugs (Szuster-Ciesielska, Tustanowska-Stachura, Slotwinska, Marmurowska-Michalowska, & Kandefor-Szerszen, 2003). Further screening could involve measuring peripheral blood for IL-1 $\beta$ , IL-6, TNF and C-reactive protein (CRP), which are the most reliable biomarkers of inflammation in patients with depression (Miller, Maletic, & Raison, 2009).

### **Summary**

In pursuit of investigating the neuroinflammation process, neuroimaging offers a non-invasive method for the purpose of identification, understanding, and therapeutic targeting. Proposed neuroimaging proof-of-concept (PoC) research is much needed so that surrogate end-points for clinical trials can be uncovered. Further,



neuroimaging may provide evidence for direct inflammation-depression dependence, prior to simply prescribing anti-inflammatory medications to those with depression. The imaging modality may also create a desirable end-point for treatment efficacy. Without this, the efficacy of such complex pharmacotherapy attempts will likely hit the same plateau that conventional monoamine-based antidepressants have faced unless a better understanding of the molecular basis of depression and subgrouping of patients is done to provide proof-of-concept evidence (Gelenberg et al., 2008). Drug trials seem to be premature in the absence of sufficient knowledge on the pathophysiological mechanisms linking inflammation to depression.

Neuropsychiatric disorders such as depression are typically long-term illnesses; the short-term effect of putative disease-modifying agents is best demonstrated using valid, objective surrogate endpoints that respond to the mechanistic effects of the intervention. Unfortunately, to date no such reliable endpoints exist for measuring the effects of intervening to modulate brain inflammation. This is a major impediment in the conversion of promising molecules from animal studies to human trials. The proposed PoC study is an explicit attempt to test a noninvasive neuroimaging measure (combined FEPPA and GluCEST) that can potentially serve as a marker of response to the modulation of the brain's inflammatory response. Secondly, an excess of inflammatory activity in the brain is likely to be common across many brain disorders and thus a fairly non-specific target for intervention. Further, the possibility of identifying a subgroup of subjects in whom inflammation-related excitotoxicity is marked, provides an objective means to conduct stratified clinical trials specific to this group, potentially enhancing success rates.

Interesting results supporting a role for anti-inflammatory drugs as adjuvants to reduce depressive symptoms have emerged in recent times (Kohler et al., 2014; Kohler, Petersen, Mors, & Gasse, 2015). Mental health drug discovery has

entered a crucial phase, where advances in understanding the link between inflammation and psychiatric disease expression could prove to be a game-changer to create exciting opportunities. Our proposed PoC study is well-poised to fill this gap.

## References

- Alexopoulos, G. S., & Morimoto, S. S. (2011). The inflammation hypothesis in geriatric depression. *International Journal of Geriatric Psychiatry*, *26*(11), 1109-1118. doi:10.1002/gps.2672
- American Psychiatric Association. (2013). *Diagnostic and statistical manual of mental disorders : DSM-5* (5th ed.). Arlington, VA: American Psychiatric Association.
- Arakawa, S., Shirayama, Y., Fujita, Y., Ishima, T., Horio, M., Muneoka, K., . . . Hashimoto, K. (2012). Minocycline produced antidepressant-like effects on the learned helplessness rats with alterations in levels of monoamine in the amygdala and no changes in BDNF levels in the hippocampus at baseline. *Pharmacology, Biochemistry and Behavior*, *100*(3), 601-606. doi:10.1016/j.pbb.2011.09.008
- Beyer, T., Townsend, D. W., Brun, T., Kinahan, P. E., Charron, M., Roddy, R., . . . Nutt, R. (2000). A combined PET/CT scanner for clinical oncology. *Journal of Nuclear Medicine*, *41*(8), 1369-1379.
- Bloomfield, P. S., Selvaraj, S., Veronese, M., Rizzo, G., Bertoldo, A., Owen, D. R., . . . Howes, O. D. (2016). Microglial Activity in People at Ultra High Risk of Psychosis and in Schizophrenia: An [(11)C]PBR28 PET Brain Imaging Study. *American Journal of Psychiatry*, *173*(1), 44-52. doi:10.1176/appi.ajp.2015.14101358
- Bourgeat, P., Chetelat, G., Villemagne, V. L., Fripp, J., Raniga, P., Pike, K., . . . Group, A. R.

- (2010). Beta-amyloid burden in the temporal neocortex is related to hippocampal atrophy in elderly subjects without dementia. *Neurology*, *74*(2), 121-127. doi:10.1212/WNL.0b013e3181c918b5
- Brix, G., & Beyer, T. (2005). PET/CT: dose-escalated image fusion? *Nuklearmedizin*, *44 Suppl 1*, S51-57.
- Bunney, W. E., Jr., & Davis, J. M. (1965). Norepinephrine in depressive reactions. A review. *Archives of General Psychiatry*, *13*(6), 483-494.
- Cai, K., Haris, M., Singh, A., Kogan, F., Greenberg, J. H., Hariharan, H., . . . Reddy, R. (2012). Magnetic resonance imaging of glutamate. *Nature Medicine*, *18*(2), 302-306. doi:10.1038/nm.2615
- Cai, K., Singh, A., Roalf, D. R., Nanga, R. P., Haris, M., Hariharan, H., . . . Reddy, R. (2013). Mapping glutamate in subcortical brain structures using high-resolution GluCEST MRI. *NMR in Biomedicine*, *26*(10), 1278-1284. doi:10.1002/nbm.2949
- Charney, D. S. (1998). Monoamine dysfunction and the pathophysiology and treatment of depression. *Journal of Clinical Psychiatry*, *59 Suppl 14*, 11-14.
- Delgado, P. L. (2000). Depression: the case for a monoamine deficiency. *Journal of Clinical Psychiatry*, *61 Suppl 6*, 7-11.
- Disselhorst, J. A., Bezrukov, I., Kolb, A., Parl, C., & Pichler, B. J. (2014). Principles of PET/MR Imaging. *Journal of Nuclear Medicine*, *55*(Supplement 2), 2S-10S. doi:10.2967/jnumed.113.129098
- Dowlati, Y., Herrmann, N., Swardfager, W., Liu, H., Sham, L., Reim, E. K., & Lanctot, K. L. (2010). A meta-analysis of cytokines in major depression. *Biological Psychiatry*, *67*(5), 446-457. doi:10.1016/j.biopsych.2009.09.033
- Duval, F., Mokrani, M. C., Monreal-Ortiz, J. A., Fattah, S., Champeval, C., Schulz, P., & Macher, J. P. (2006). Cortisol hypersecretion in unipolar major depression with melancholic and psychotic features: dopaminergic, noradrenergic and thyroid correlates. *Psychoneuroendocrinology*, *31*(7), 876-888. doi:10.1016/j.psyneuen.2006.04.003
- Ehret, M., & Sobieraj, D. M. (2014). Prevention of interferon-alpha-associated depression with antidepressant medications in patients with hepatitis C virus: a systematic review and meta-analysis. *International Journal of Clinical Practice*, *68*(2), 255-261. doi:10.1111/ijcp.12268
- Frick, L. R., Williams, K., & Pittenger, C. (2013). Microglial dysregulation in psychiatric disease. *Clinical & Developmental Immunology*, *2013*, 608654. doi:10.1155/2013/608654
- Friedrich, M. J. (2014). Research on psychiatric disorders targets inflammation. *Journal of the American Medical Association*, *312*(5), 474-476. doi:10.1001/jama.2014.8276
- Gelenberg, A. J., Thase, M. E., Meyer, R. E., Goodwin, F. K., Katz, M. M., Kraemer, H. C., . . . Rosenbaum, J. F. (2008). The history and current state of antidepressant clinical trial design: a call to action for proof-of-concept studies. *Journal of Clinical Psychiatry*, *69*(10), 1513-1528.
- Goodwin, G. M. (2015). The overlap between anxiety, depression, and obsessive-compulsive disorder. *Dialogues in Clinical Neuroscience*, *17*(3), 249-260.
- Hannestad, J., DellaGioia, N., & Bloch, M. (2011). The effect of antidepressant medication

- treatment on serum levels of inflammatory cytokines: a meta-analysis. *Neuropsychopharmacology*, 36(12), 2452-2459. doi:10.1038/npp.2011.132
- Harrison, N. A., Brydon, L., Walker, C., Gray, M. A., Steptoe, A., Dolan, R. J., & Critchley, H. D. (2009). Neural origins of human sickness in interoceptive responses to inflammation. *Biological Psychiatry*, 66(5), 415-422. doi:10.1016/j.biopsych.2009.03.007
- Hasler, G., Drevets, W. C., Manji, H. K., & Charney, D. S. (2004). Discovering endophenotypes for major depression. *Neuropsychopharmacology*, 29(10), 1765-1781. doi:10.1038/sj.npp.1300506
- Hicks, R., Lau, E., & Binns, D. (2007). Hybrid imaging is the future of molecular imaging. *Biomedical Imaging and Intervention Journal*, 3(3), e49. doi:10.2349/bijj.3.3.e49
- Hirschfeld, R. M. (2000). History and evolution of the monoamine hypothesis of depression. *Journal of Clinical Psychiatry*, 61 Suppl 6, 4-6.
- Hricak, H., Choi, B. I., Scott, A. M., Sugimura, K., Muellner, A., von Schulthess, G. K., . . . Larson, S. M. (2010). Global trends in hybrid imaging. *Radiology*, 257(2), 498-506. doi:10.1148/radiol.10100579
- Huettel, S. A., Song, A. W., & McCarthy, G. (2009). Functional magnetic resonance imaging (2ed).
- Kohler, O., Benros, M. E., Nordentoft, M., Farkouh, M. E., Iyengar, R. L., Mors, O., & Krogh, J. (2014). Effect of anti-inflammatory treatment on depression, depressive symptoms, and adverse effects: a systematic review and meta-analysis of randomized clinical trials. *JAMA Psychiatry*, 71(12), 1381-1391. doi:10.1001/jamapsychiatry.2014.1611
- Kohler, O., Petersen, L., Mors, O., & Gasse, C. (2015). Inflammation and depression: combined use of selective serotonin reuptake inhibitors and NSAIDs or paracetamol and psychiatric outcomes. *Brain and Behavior*, 5(8), e00338. doi:10.1002/brb3.338
- Krishnadas, R., & Cavanagh, J. (2012). Depression: an inflammatory illness? *Journal of Neurology, Neurosurgery and Psychiatry*, 83(5), 495-502. doi:10.1136/jnnp-2011-301779
- Logothetis, N. K., & Pfeuffer, J. (2004). On the nature of the BOLD fMRI contrast mechanism. *Magnetic Resonance Imaging*, 22(10), 1517-1531. doi:10.1016/j.mri.2004.10.018
- Madeeh Hashmi, A., Awais Aftab, M., Mazhar, N., Umair, M., & Butt, Z. (2013). The fiery landscape of depression: A review of the inflammatory hypothesis. *Pakistan Journal of Medical Science*, 29(3), 877-884.
- Maes, M., Leonard, B., Fernandez, A., Kubera, M., Nowak, G., Veerhuis, R., . . . Berk, M. (2011). (Neuro)inflammation and neuroprogression as new pathways and drug targets in depression: from antioxidants to kinase inhibitors. *Progress in Neuro-Psychopharmacology and Biological Psychiatry*, 35(3), 659-663. doi:10.1016/j.pnpbp.2011.02.019
- Margaretten, M., Julian, L., Katz, P., & Yelin, E. (2011). Depression in patients with rheumatoid arthritis: description, causes and mechanisms. *International Journal of Clinical Rheumatology*, 6(6), 617-623. doi:10.2217/IJR.11.6
- Mark, L. P., Prost, R. W., Ulmer, J. L., Smith, M. M., Daniels, D. L., Strottmann, J. M., . . . Hacein-Bey, L. (2001). Pictorial review of glutamate excitotoxicity: fundamental concepts for neuroimaging. *AJNR: American Journal of Neuroradiology*, 22(10), 1813-1824.

- Miller, A. H., Maletic, V., & Raison, C. L. (2009). Inflammation and its discontents: the role of cytokines in the pathophysiology of major depression. *Biological Psychiatry*, *65*(9), 732-741. doi:10.1016/j.biopsych.2008.11.029
- Miller, A. H., & Raison, C. L. (2016). The role of inflammation in depression: from evolutionary imperative to modern treatment target. *Nature Reviews: Immunology*, *16*(1), 22-34. doi:10.1038/nri.2015.5
- Mori, T., Maeda, J., Shimada, H., Higuchi, M., Shinotoh, H., Ueno, S., & Suhara, T. (2012). Molecular imaging of dementia. *Psychogeriatrics*, *12*(2), 106-114. doi:10.1111/j.1479-8301.2012.00409.x
- Nestler, E. J. (2014). Epigenetic mechanisms of depression. *JAMA Psychiatry*, *71*(4), 454-456. doi:10.1001/jamapsychiatry.2013.4291
- Ory, D., Celen, S., Verbruggen, A., & Bormans, G. (2014). PET radioligands for in vivo visualization of neuroinflammation. *Current Pharmaceutical Design*, *20*(37), 5897-5913.
- Palaniyappan, L., & Liddle, P. F. (2012). Does the salience network play a cardinal role in psychosis? An emerging hypothesis of insular dysfunction. *Journal of Psychiatry and Neuroscience*, *37*(1), 17-27. doi:10.1503/jpn.100176
- Palaniyappan, L., White, T. P., & Liddle, P. F. (2012). The concept of salience network dysfunction in schizophrenia: from neuroimaging observations to therapeutic opportunities. *Current Topics in Medicinal Chemistry*, *12*(21), 2324-2338.
- Pasternak, O., Kubicki, M., & Shenton, M. E. (2016). In vivo imaging of neuroinflammation in schizophrenia. *Schizophrenia Research*, *173*(3), 200-212. doi:10.1016/j.schres.2015.05.034
- Pasternak, O., Westin, C. F., Dahlben, B., Bouix, S., & Kubicki, M. (2015). The extent of diffusion MRI markers of neuroinflammation and white matter deterioration in chronic schizophrenia. *Schizophrenia Research*, *161*(1), 113-118. doi:10.1016/j.schres.2014.07.031
- Petrik, D., Lagace, D. C., & Eisch, A. J. (2012). The neurogenesis hypothesis of affective and anxiety disorders: are we mistaking the scaffolding for the building? *Neuropharmacology*, *62*(1), 21-34. doi:10.1016/j.neuropharm.2011.09.003
- Pichler, B. J., Judenhofer, M. S., & Pfannenberger, C. (2008). Multimodal imaging approaches: PET/CT and PET/MRI. *Handbook of Experimental Pharmacology* (185 Pt 1), 109-132. doi:10.1007/978-3-540-72718-7\_6
- Raison, C. L., Felger, J. C., & Miller, A. H. (2013). Inflammation and treatment resistance in major depression: The perfect storm. *Psychiatric Times*, *30*(9), September 12.
- Rowe, C. C., Ackerman, U., Browne, W., Mulligan, R., Pike, K. L., O'Keefe, G., . . . Villemagne, V. L. (2008). Imaging of amyloid beta in Alzheimer's disease with 18F-BAY94-9172, a novel PET tracer: proof of mechanism. *Lancet Neurology*, *7*(2), 129-135. doi:10.1016/S1474-4422(08)70001-2
- Ruhe, H. G., Mason, N. S., & Schene, A. H. (2007). Mood is indirectly related to serotonin, norepinephrine and dopamine levels in humans: a meta-analysis of monoamine depletion studies. *Molecular Psychiatry*, *12*(4), 331-359. doi:10.1038/sj.mp.4001949
- Rush, A. J., Trivedi, M. H., Wisniewski, S. R., Nierenberg, A. A., Stewart, J. W., Warden, D., . . . Fava, M. (2006). Acute and longer-term outcomes in depressed outpatients requiring one or several treatment steps: a STAR\*D report.

- American Journal of Psychiatry*, 163(11), 1905-1917. doi:10.1176/ajp.2006.163.11.1905
- Salomon, R. M., Miller, H. L., Krystal, J. H., Heninger, G. R., & Charney, D. S. (1997). Lack of behavioral effects of monoamine depletion in healthy subjects. *Biological Psychiatry*, 41(1), 58-64.
- Sanacora, G., Treccani, G., & Popoli, M. (2012). Towards a glutamate hypothesis of depression: an emerging frontier of neuropsychopharmacology for mood disorders. *Neuropharmacology*, 62(1), 63-77. doi:10.1016/j.neuropharm.2011.07.036
- Sandiego, C. M., Gallezot, J. D., Pittman, B., Nabulsi, N., Lim, K., Lin, S. F., . . . Cosgrove, K. P. (2015). Imaging robust microglial activation after lipopolysaccharide administration in humans with PET. *Proceedings of the National Academy of Sciences of the United States of America*, 112(40), 12468-12473. doi:10.1073/pnas.1511003112
- Schildkraut, J. J. (1965). The catecholamine hypothesis of affective disorders: a review of supporting evidence. *American Journal of Psychiatry*, 122(5), 509-522. doi:10.1176/ajp.122.5.509
- Schlemmer, H. P., Pichler, B. J., Schmand, M., Burbar, Z., Michel, C., Ladebeck, R., . . . Claussen, C. D. (2008). Simultaneous MR/PET imaging of the human brain: feasibility study. *Radiology*, 248(3), 1028-1035. doi:10.1148/radiol.2483071927
- Schulberg, H. C., Katon, W., Simon, G. E., & Rush, A. J. (1998). Treating major depression in primary care practice: an update of the Agency for Health Care Policy and Research Practice Guidelines. *Archives of General Psychiatry*, 55(12), 1121-1127.
- Setiawan, E., Wilson, A. A., Mizrahi, R., Rusjan, P. M., Miler, L., Rajkowska, G., . . . Meyer, J. H. (2015). Role of translocator protein density, a marker of neuroinflammation, in the brain during major depressive episodes. *JAMA Psychiatry*, 72(3), 268-275. doi:10.1001/jamapsychiatry.2014.2427
- Slomka, P. J. (2004). Software approach to merging molecular with anatomic information. *Journal of Nuclear Medicine*, 45 Suppl 1, 36S-45S.
- Szuster-Ciesielska, A., Tustanowska-Stachura, A., Slotwinska, M., Marmurowska-Michalowska, H., & Kandefler-Szerszen, M. (2003). In vitro immunoregulatory effects of antidepressants in healthy volunteers. *Polish Journal of Pharmacology*, 55(3), 353-362.
- Tansey, M. G. (2010). Inflammation in neuropsychiatric disease. *Neurobiology of Disease*, 37(3), 491-492. doi:10.1016/j.nbd.2009.12.004
- Theberge, J., Bartha, R., Drost, D. J., Menon, R. S., Malla, A., Takhar, J., . . . Williamson, P. C. (2002). Glutamate and glutamine measured with 4.0 T proton MRS in never-treated patients with schizophrenia and healthy volunteers. *American Journal of Psychiatry*, 159(11), 1944-1946. doi:10.1176/appi.ajp.159.11.1944
- Theberge, J., Williamson, K. E., Aoyama, N., Drost, D. J., Manchanda, R., Malla, A. K., . . . Williamson, P. C. (2007). Longitudinal grey-matter and glutamatergic losses in first-episode schizophrenia. *British Journal of Psychiatry*, 191, 325-334. doi:10.1192/bjp.bp.106.033670
- Townsend, D. W. (2008). Multimodality imaging of structure and function. *Physics in Medicine and Biology*, 53(4), R1-R39. doi:10.1088/0031-9155/53/4/R01

Uher, R., Mors, O., Rietschel, M., Rajewska-Rager, A., Petrovic, A., Zobel, A., . . . McGuffin, P. (2011). Early and delayed onset of response to antidepressants in individual trajectories of change during treatment of major depression: a secondary analysis of data from the Genome-Based Therapeutic Drugs for Depression (GENDEP) study. *Journal of Clinical Psychiatry*, *72*(11), 1478-1484. doi:10.4088/JCP.10m06419

Yirmiya, R., Rimmerman, N., & Reshef, R. (2015). Depression as a microglial disease. *Trends in Neurosciences*, *38*(10), 637-658. doi:10.1016/j.tins.2015.08.001

Zarate, C., Jr., Machado-Vieira, R., Henter, I., Ibrahim, L., Diazgranados, N., & Salvadore, G. (2010). Glutamatergic modulators: the future of treating mood disorders? *Harvard Review of Psychiatry*, *18*(5), 293-303. doi:10.3109/10673229.2010.511059